

Spontaneous septostomy in mono-chorionic diamniotic twins resulting in cord entanglement and fetal demise

Abstract

Monoamniotic twins are known to be at risk of cord entanglement, and have an elevated perinatal morbidity and mortality associated with this. We present a case of cord entanglement in a monochorionic diamniotic (MCDA) twin pregnancy thought to be due to spontaneous septostomy. Unfortunately the cord entanglement was detected postpartum, and ultimately resulted in the demise of one of the twins. Literature review reveals this as a recognised, albeit rare, phenomena.

Keywords: cord entanglement, monoamniotic twins, monochorionic diamniotic (MCDA) twin, spontaneous septostomy.

Tina Fleming¹

MBBS, MRANZCOG
Obstetric and Gynaecology
Fellow

Trent Miller²

MBBS, FRANZCOG
Obstetric and Gynaecology
Staff Specialist

¹Royal Prince Alfred
Hospital
Camperdown
New South Wales
Australia

²St George Hospital
Kogarah
New South Wales
Australia

Correspondence to email
tinaannemartino@
gmail.com

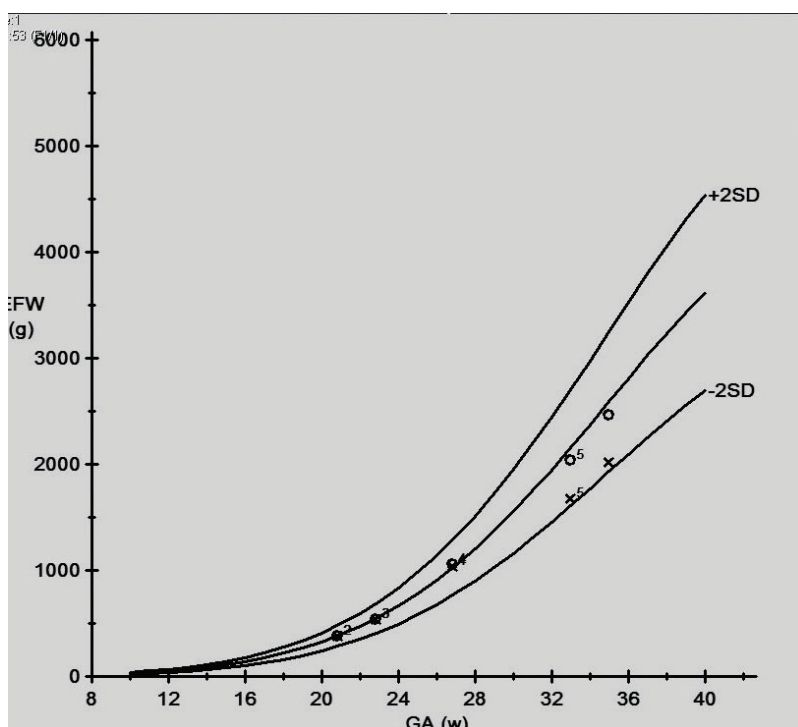


Figure 1: Growth Velocity for Twin A and Twin B.

Case study

Our patient is a 28-year-old gravida 2, para 1 with a history of one prior uncomplicated term vaginal delivery. She had a normal body mass index, was a non-smoker and had no significant medical history. A referral to high risk antenatal care was made due to a diagnosis of monochorionic, diamniotic (MCDA) twins in this pregnancy, when chorionicity had been determined during an early first trimester ultrasound and confirmed at her nuchal translucency scan (NTS). All antenatal serology was unremarkable and the NTS demonstrated a low risk for trisomy for both twins.

Morphology ultrasound was revealed structurally normal fetuses, however a two-vessel cord was noted for Twin A. All other features of fetal wellbeing were reassuring, including size and umbilical dopplers. Of note, the membrane between the twins was clearly visualised and documented on this scan in addition to the first trimester images.

According to hospital protocol, the patient underwent fortnightly ultrasounds from 24 weeks gestation to assess fetal growth and wellbeing which confirmed satisfactory interval growth for both twins. The first point of concern arose at 33 + 2 weeks of gestation when an isolated finding

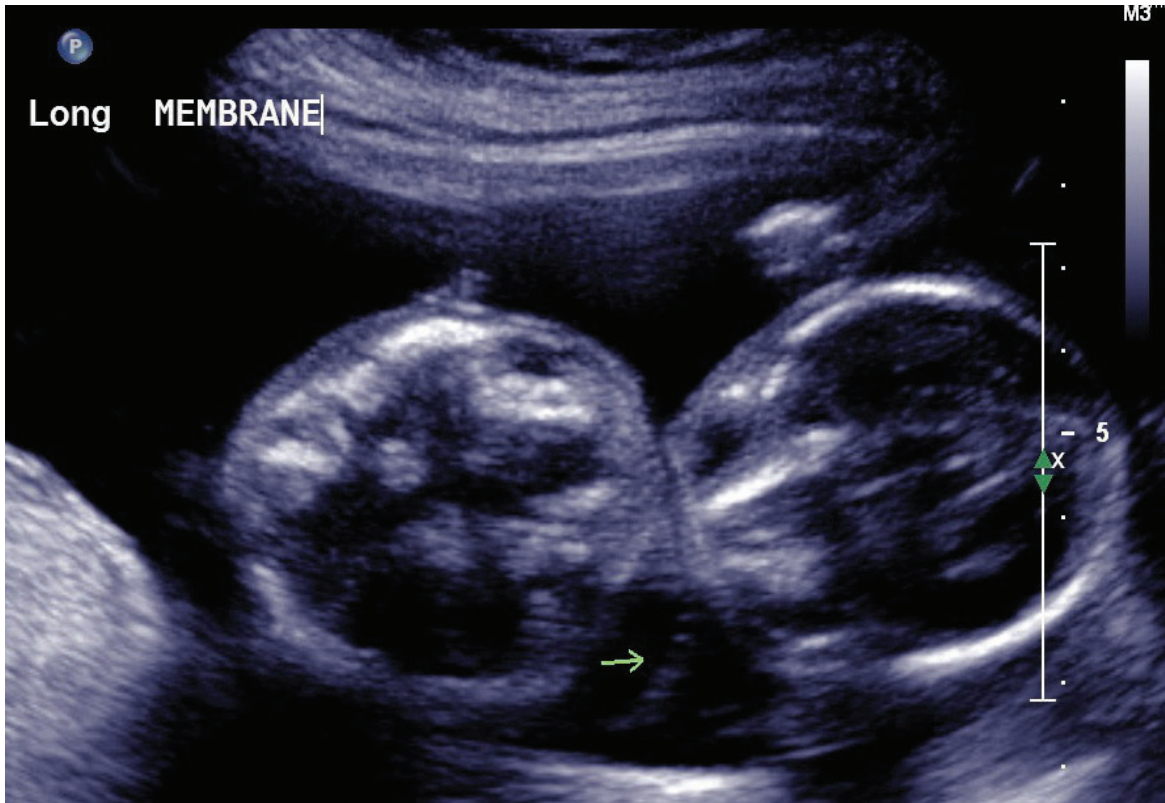


Figure 2: Final ultrasound scan demonstrating intertwin dividing membrane.

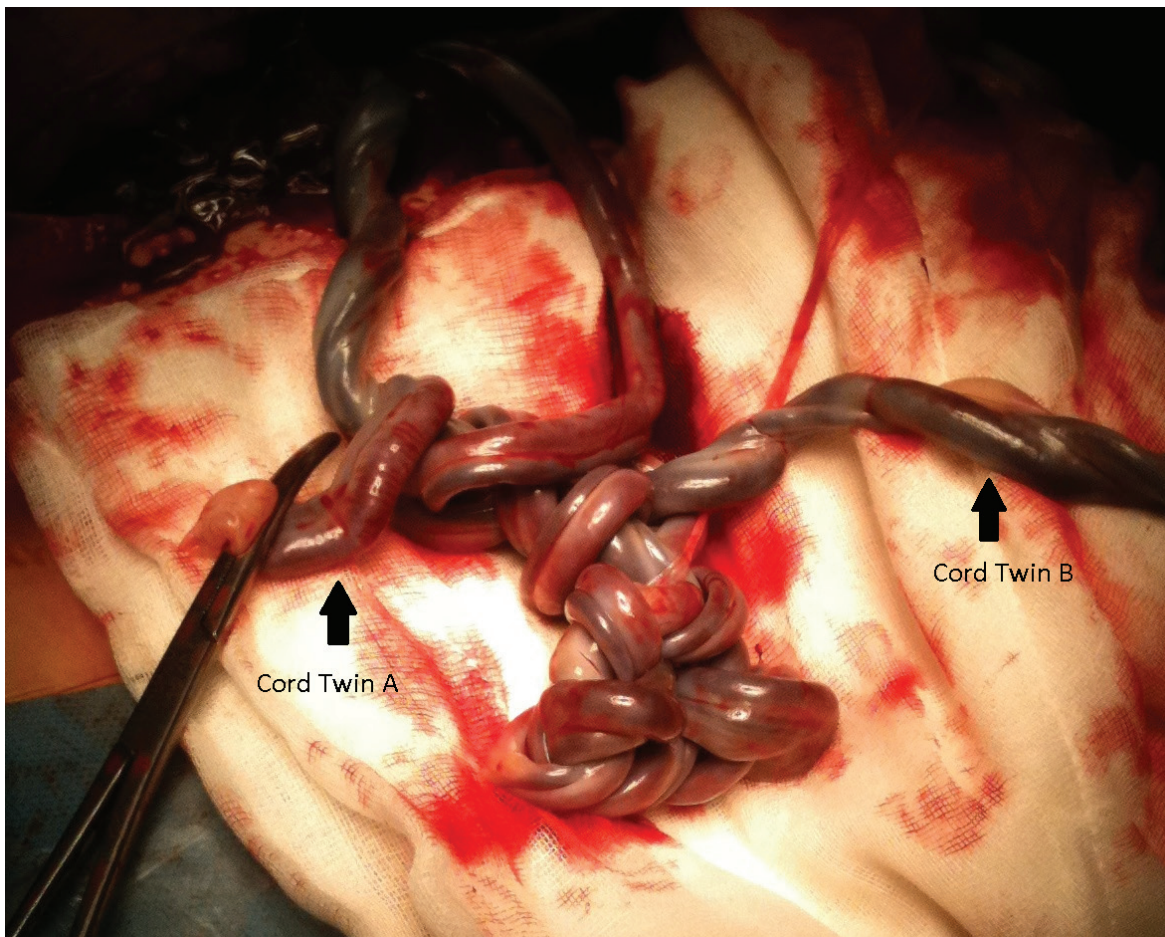


Figure 3: Image of cord entanglement.

Table 1: Spontaneous septostomy in diamniotic twins in literature 1991–2011.¹⁻⁹

Author	Year	Chorionicity	Time of diagnosis	Cord Entanglement	Mode of delivery	Timing of delivery	Outcome
Krause and Goh	1998	MCDA	Postnatal	Yes	CS	39/40	TA & TB – live birth
Chmait, <i>et al.</i> (1)	2009	MCDA	20/40	No	CS	27/40	TA & TB – live birth
Chmait, <i>et al.</i> (2)	2009	MCDA	17/40	No	VD	22/40	TOP due to TTTS
Chmait, <i>et al.</i> (3)	2009	MCDA	20/40	No	VD	34/40	TA & TB – live birth
Chmait, <i>et al.</i> (4)	2009	MCDA	19/40	Yes	VD	38/40	TA – live birth TB – selective TOP
Sherer, <i>et al.</i>	2005	MCDA	26/40	Yes	CS	34/40	TA & TB – live birth
Jeanty, <i>et al.</i> (1)	2010	DCDA	19/40	No	CS	34/40	TA & TB – live birth
Jeanty, <i>et al.</i> (2)	2010	DCDA	21/40	No	CS	31/40	TA & TB – live birth
Gilbert, <i>et al.</i> (1)	1991	MCDA	Postnatal	No	VD	25/40	TA & TB – stillbirth
Gilbert, <i>et al.</i> (2)	1991	MCDA	Postnatal	No	CS	27/40	TA – live birth TB – stillbirth
Gilbert, <i>et al.</i> (3)	1991	MCDA	Postnatal	Yes	CS	30/40	TA & TB – live birth
Gilbert, <i>et al.</i> (4)	1991	MCDA	Postnatal	No	CS	32/40	TA & TB – live birth
Nasrallah and Faden	2005	MCDA	Postnatal	Yes	TA - VD, TB - CS	36/40	TA – live birth, TB – severe HIE
Yoshimura, <i>et al.</i>	2009	MCDA	24/40	Yes	CS	32/40	TA & TB – live birth
Chen, <i>et al.</i>	1994	MCDA	26/40	Yes	CS	37/40	TA & TB – live birth

MCDA = Mono chorionic, Diamniotic; DCDA = Dichorionic, Diamniotic; CS = Caesarean section; VD = Vaginal delivery; TA = Twin A; TB = Twin B; HIE = Hypoxic Ischaemic Encephalopathy

of increased pulsatility index (> 95%) for ductus venosus was noted for Twin B. Umbilical and middle cerebral artery (MCA) dopplers were normal. Betamethasone was administered for fetal lung maturation at this time. Repeat Doppler and liquor assessment four and eight days later showed the pulsatility index for umbilical artery, MCA and ductus venosus to be within normal limits for both Twin A and Twin B. Normal cardiotocograms were also confirmed following each ultrasound visit.

Formal growth scanning fourteen days later at 35 + 2 weeks gestation confirmed a growth discrepancy such that Twin A demonstrated symmetric growth on the 5th centile, and Twin B with symmetric growth on the 35th centile as revealed in Figure 1. The twins were presenting cephalic/cephalic and after extensive discussion a decision was made to proceed to an induction of labour at 35 + 6 weeks gestation. Figure 2 demonstrates the persistent septum between the twins visualised on the final ultrasound scan.

On presentation to the delivery suite on the morning of planned induction, the fetal heart for Twin A was unable to be visualised.

There were no prior concerns regarding a reduction in fetal movements. At emergency caesarean section, Twin A was delivered as a fresh stillborn weighing 2300 g, and Twin B was delivered not requiring resuscitation with arterial cord pH 7.185 and base excess -5.1 weighing 2100 g. It was noted at the time of caesarean that the umbilical cords were extensively intertwined as demonstrated in Figure 2, suggestive of an antenatal spontaneous septostomy.

Maternal post operative recovery was unremarkable. Placental histology demonstrated areas of infarction, but no funisitis or chorioamnionitis. Microscopic sections of the probable common membrane show two segments of amnion separated by proteinaceous debris, however it was unable to categorically confirm the diamniotic nature of the pregnancy.

Discussion

Although twin pregnancies account for around 1% of all pregnancies, multiple gestations are associated with more than 10% of perinatal deaths (Gilbert, 1991).¹ This is largely due to spontaneous and iatrogenic prematurity. Monoamniotic twins,

which represent 1% of all twins, have a high perinatal mortality rate (30–70%), with the most common cause of fetal death being cord entanglement (Gilbert, 1991). Monochorionic, diamniotic (MCDA), and dichorionic, diamniotic (DCDA) twins have an intervening amniotic membrane and therefore are not usually thought to be at risk for this complication.

Septostomy of the membrane dividing diamniotic twins has been reported primarily in monochorionic pregnancies. Jeanty, 2010, reported the first cases of DCDA twins with antenatal and postnatal confirmation of spontaneous septostomy. Spontaneous septostomy has been defined in the literature when diamnionicity has been confirmed in early pregnancy, then one of the following features noted: umbilical cord entanglement (diagnosed antenatally or postnatally), twins occupying both sides of the dividing membrane or twin-twin transfusion syndrome (TTTS) where there is polyhydramnios in the donor's sac despite a collapsed donor bladder (Chmait, 2009).² Patients who had an invasive procedure prior to the diagnosed septostomy were not included for the purpose of this review as "spontaneous".

A US case series of complicated MCDA twins referred to a maternal-fetal medicine unit for consideration of invasive fetal therapy reports the rate of spontaneous septostomy was as high as 1.8% (Chmait, 2009). Given the few cases reported in the literature, this estimate is likely to be higher than what could be expected in the standard twin population. Jeanty et al reported the first cases of DCDA twins with antenatal and postnatal confirmation of spontaneous septostomy.

As demonstrated in Table 1, nine of the fifteen reported cases of spontaneous septostomy were diagnosed with antenatal ultrasound. Cord entanglement was present in almost half of cases. Of all cases, there were five pregnancies where the outcome was significantly affected by the septostomy. These cases included two where both twins demised, and three where one twin survived and the other twin died or suffered significant hypoxic injury. In keeping with the known high incidence of prematurity with MCDA and MCMA twins, eleven of the fifteen cases (73%) were delivered (either spontaneously or iatrogenically) prior to 35/40.

Of significance, adverse fetal outcome was more frequent when the diagnosis of septostomy occurred postpartum on clinical grounds as opposed to with antenatal ultrasound. This is consistent with the unfortunate outcome in our case study, where earlier delivery would have been suggested should there have been an antenatal suspicion of pseudomonoamnicity.

Conclusion

The incidence of spontaneous rupture of the intertwin dividing membrane is not known. Although one high-risk unit reported

rates of up to 1.8%, the few cases reported in the literature suggest that this estimate is likely to be higher than what could be expected in the standard twin population. It is suggested by the literature presented that if the diagnosis of septostomy is made antenatally, the fetal outcome may be improved, however the data is insufficient to confirm this trend. Based on the complication of cord entanglement seen in the twins with spontaneous septostomy, it would seem prudent to manage such cases as monoamniotic twins when antenatal diagnosis is possible. Sonographers and sonologists are advised to meticulously look for signs of spontaneous septostomy during regular follow up scans for MCDA or DCDA twins.

References

- 1 Gilbert WM, Davis SE, Kaplan C, Pretorius D, Merritt TA, Benirschke K Morbidity associated with prenatal disruption of the dividing membrane in twin gestations. *Obstet Gynaecol* 1991; 78 (4): 623–30.
- 2 Chmait RH, Aghajanian P, Kontopoulos EV, Quintero RA. Prenatal diagnosis of spontaneous septostomy of the dividing membranes in complicated monochorionic diamniotic multiple gestations. *JUM* 2009; 28: 663–68.
- 3 Gary A, Aisenbrey GA, Catanzarite VA, Hurley TJ, Spiegel JH, Schrimmer DB, Mendoza A. Monoamniotic and pseudomonoamniotic twins: sonographic diagnosis, detection of cord entanglement, and obstetric management. *Obstet Gynaecol* 1995; 86: 218–22.
- 4 Chen SE, Trupin L, Trupin S. Antepartum rupture of diamniotic membranes separating monozygotic twins: a case report. *J Reprod Med* 1994; 39: 67–70.
- 5 Jeanty C, Newman E, Jeanty P, Rodts-Palenik S. Prenatal diagnosis of spontaneous septostomy in dichorionic diamniotic twins and review of the literature. *JUM* 2010; 29: 455–63.
- 6 Krause HG, Goh JTW. Cord entanglement in monochorionic diamniotic twins. *Aust N Z J Obstet Gynaecol* 1998; 38: 341–42.
- 7 Nasrallah FF, Faden YA. Antepartum rupture of the inter-twin-dividing membrane in monochorionic diamniotic twins: a case report and review of the literature. *Prenat Diagn* 2005; 25 (9): 856–60.
- 8 Sherer DM, Bitton C, Stimphil R, Dalloul M, Khoury-Collado F, Abulafia O. Cord entanglement of monochorionic diamniotic twins following spontaneous antepartum septostomy sonographically simulating a true knot of the umbilical cord. *Ultrasound Obstet Gynaecol* 2005; 26: 676–8.
- 9 Yoshimura K, Yukiyo A, Inagaki H, Nakata M, Hachisuga T. Prenatal spontaneous disruption of the dividing membrane in monochorionic diamniotic twins detected at the time of fetoscopic laser coagulation. *J Obstet Gynaecol Res* 2009; 35: 1129–31.